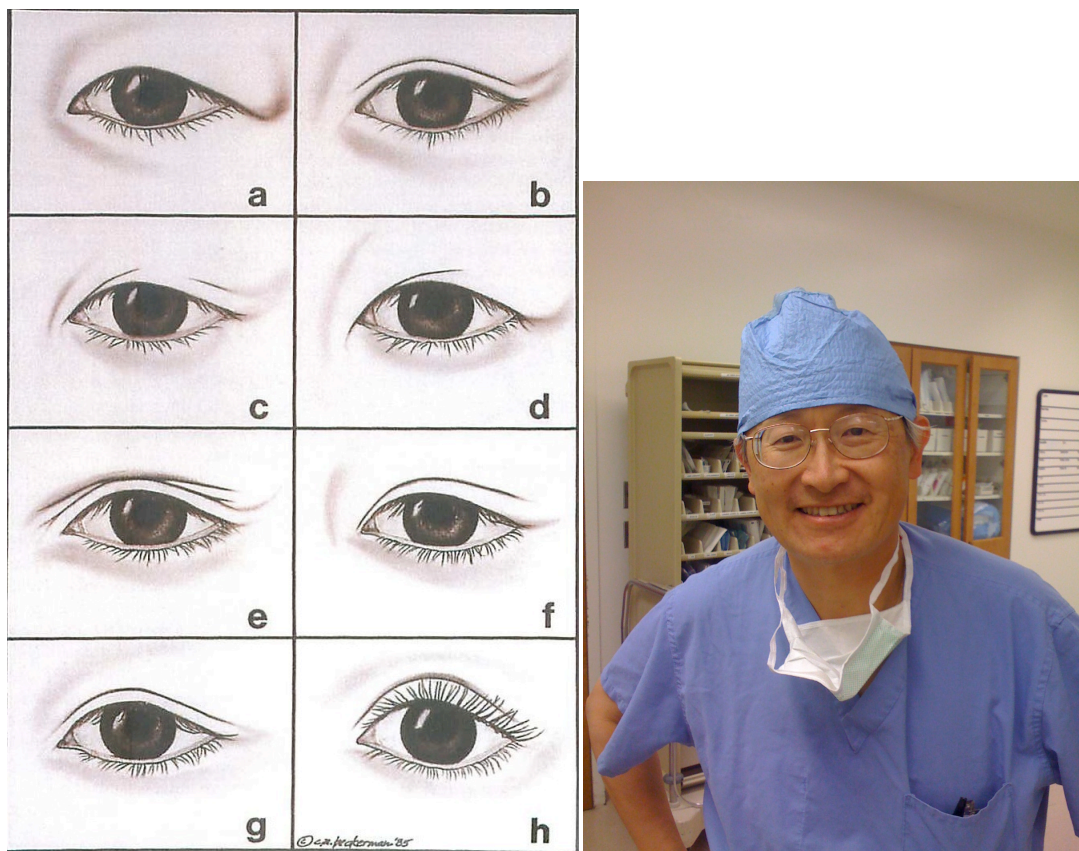


## The nano-boba Concept for Asian Blepharoplasty by C:

William P.D. Chen M.D.

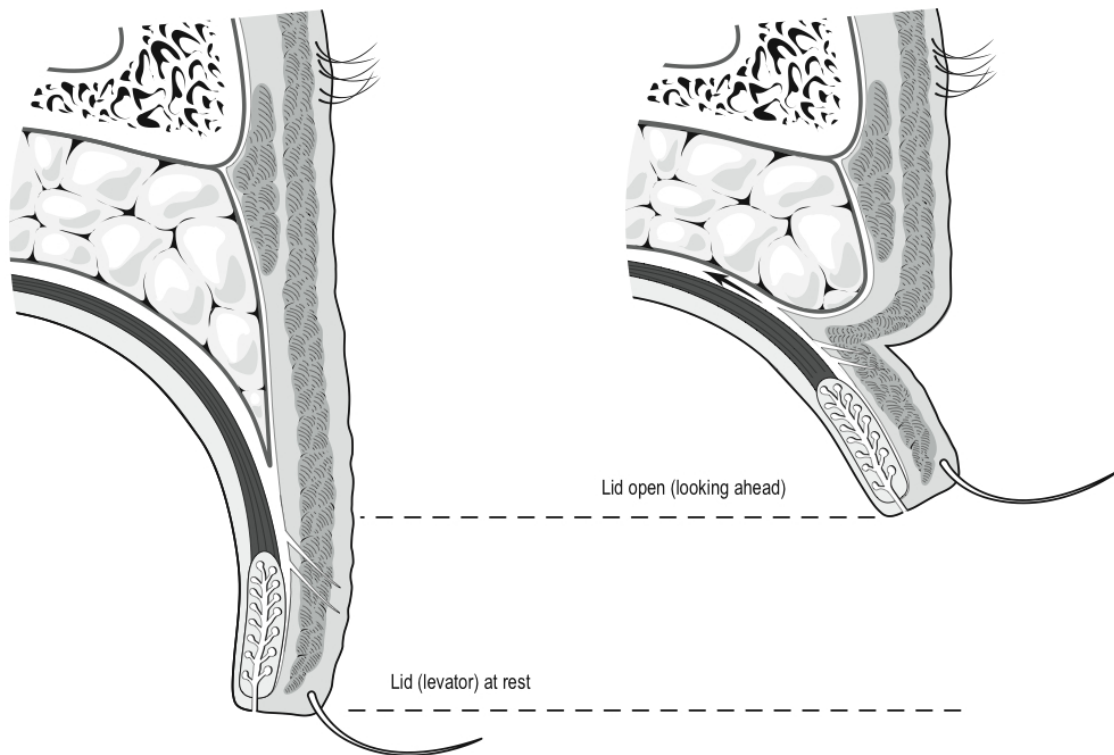
I was bored after completing my 200<sup>th</sup> cataracts surgeries in three years' eye training at UCLA and decided I like plastic surgery of the eyelids as my main area of concentration. Therefore after subspecialty fellowship training at Emory and several years' clinical private practice I find the area of double eyelid surgery really quite confusing: poor papers in the literature among several foreign languages besides English, no book of instruction, no standardized terminology; the papers published in English between 1950 and 1980 were by non-Asians.

In 1987 I coined the term "Asian Blepharoplasty" and published this article in the Journal of Ophthalmic Plastic and Reconstructive Surgery:

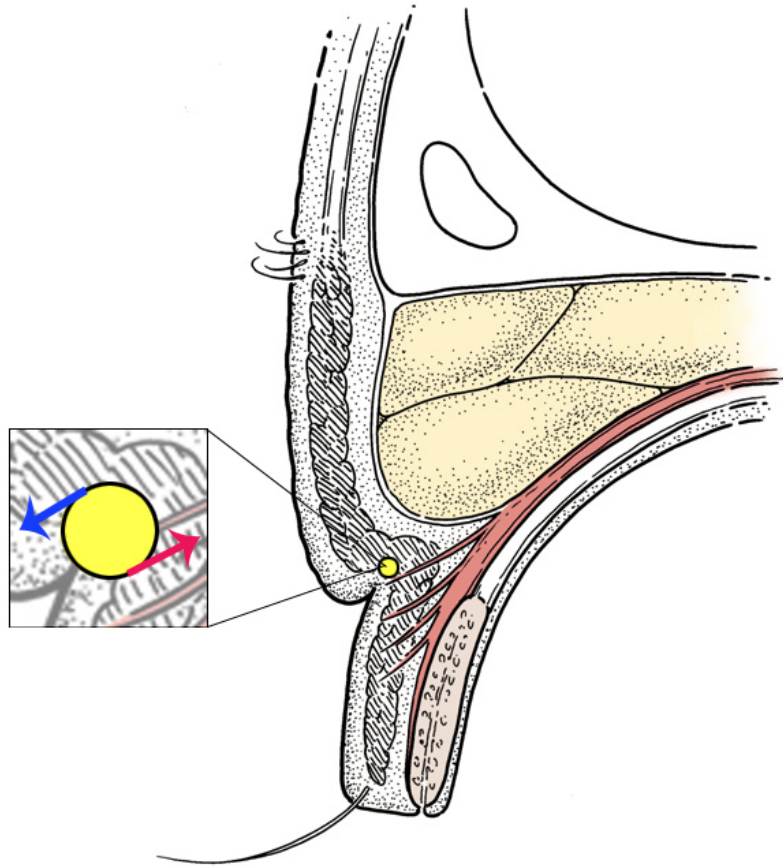


Almost thirty years later and after a dozen of papers and several surgery textbooks (actually seven), as well as teaching the topic of Asian Blepharoplasty here and abroad, here are my thoughts on double eyelid surgery:

For someone who is born with an eyelid crease, that crease occurs at a definite location among the front few layers of the eyelid just along the upper border of the tarsus (the eyelid has at least 7 layers of different tissues). *The force that forms the crease occurs between the back layer (posterior lamella + fibrous plate called tarsus) and the front layer (anterior lamella).* The tarsus is a fibrous plate that is the backbone of the upper lid margin; it is typically 7mm in vertical dimension for Asians. The levator muscle of the back layer pulls up and opens the upper lid, the front layer of skin and skeletal muscle relaxes and forms a fold of skin+muscle rolling down over the eyelid crease.(see below)



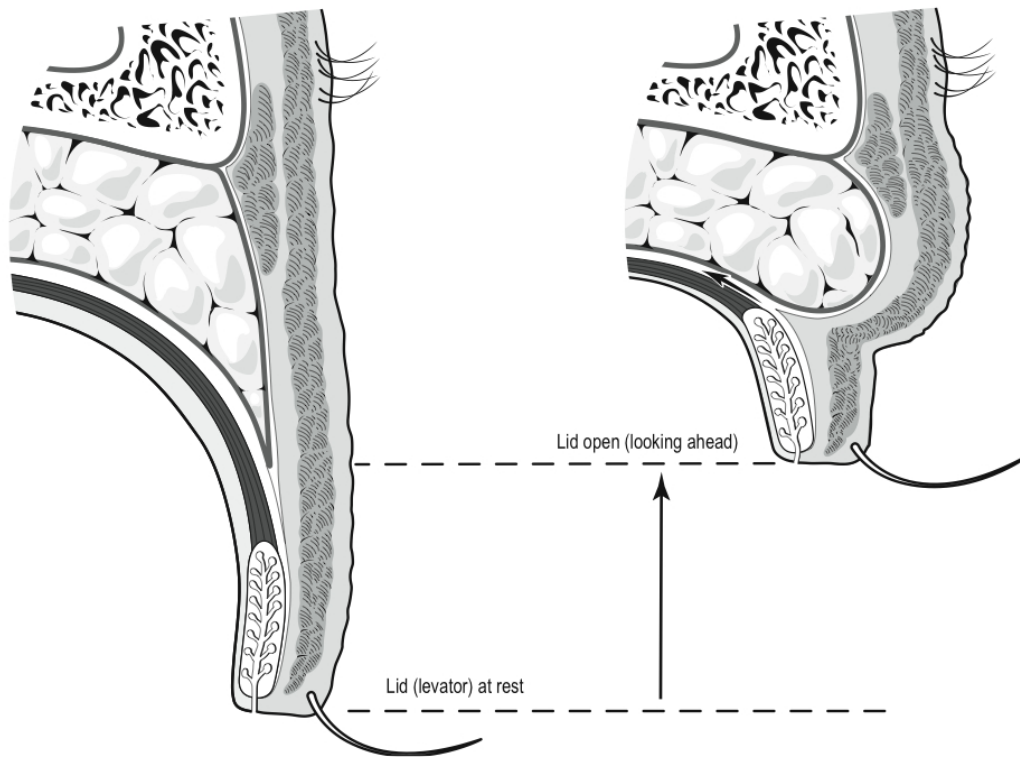
A natural double eyelid crease and its accompanying fold just above it are yin-yang to each other. What makes this possible is the *in-between area* between these two layers, this very minute *conceptual point* I call a *nano-boba* where one force pulls up (red arrow) on one surface of this nano-sphere (yellow), while an opposite-pointing force (blue) acts on the opposite surface of this nano-ball. You see that there are some minute branches of the pink levator muscle attaching to the underside of skin to form a crease. (nano is  $10^{-6}$ , a very small scale). (By *conceptual point*, we meant that it is a functional pivot, an interface where two opposite forces pass through each other; I do not mean that there are actual boba spheres inside. In Mathematics, a point is a spot in space and does not have any mass or dimension.)



When this exists, you get a fluid, life-like natural crease.  
 I will call this a “dynamic “crease.  
 (So far so good?)

For a single-lided person (about half among all Asians, including me), we are born without this sharp boundary; it is associated with a lack of these fine branching of levator muscle under the skin near where a crease should be if they were meant to be present.

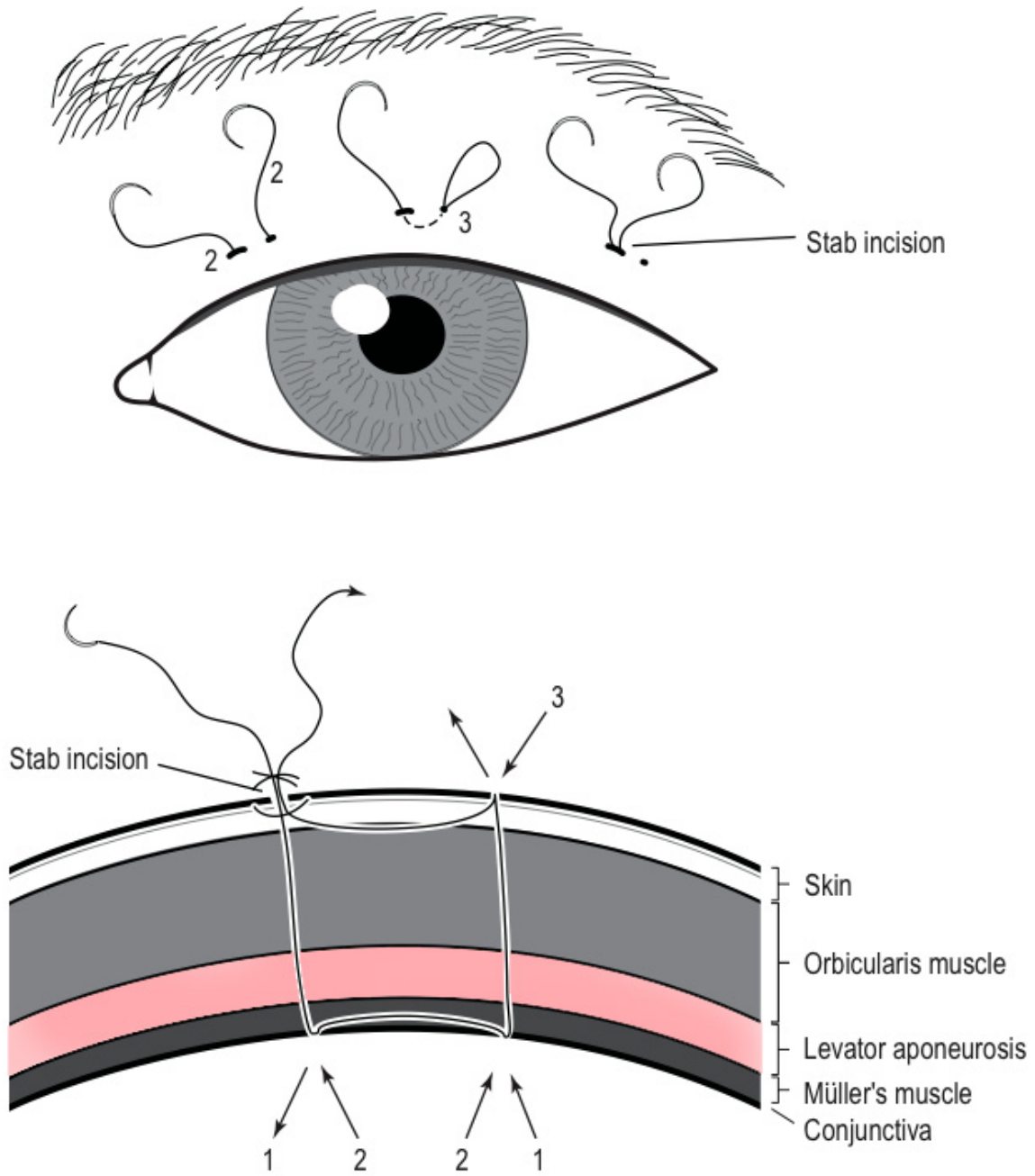
My upper lid front layer of skin/skeletal muscle bulges slightly rather than have a fold that hangs down, while the back layer (of levator) can open the lid, it did not have a clear demarcation of this yin-yang relationship, almost as if one lacked the row of tiny nano-bobas along the upper edge of the fibrous tarsus( as shown in the colored drawing above).



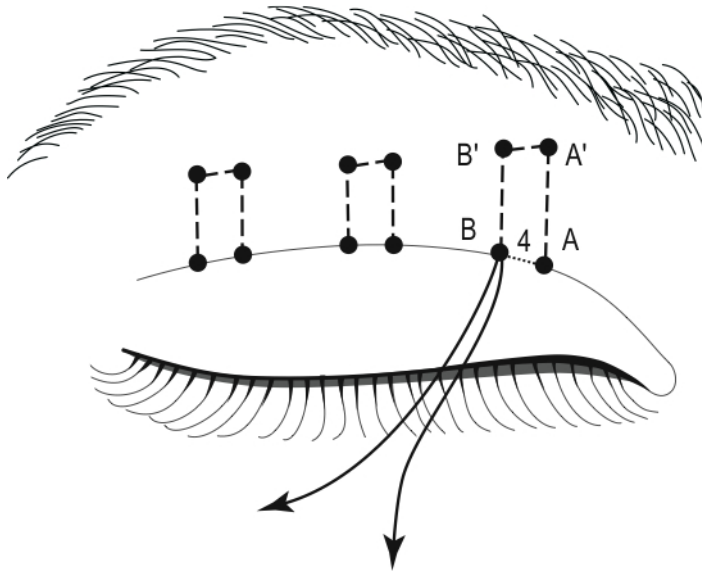
Well, how do we create a crease then?

#### SUTURE TECHNIQUE:

119 years ago, Dr. Mikamo in Japan (not sure if they had specialty differentiation back then in 1896 Japan or anywhere else) created a crease simply by fixing a series of suture material through the thickness of the upper lid, to anchor and indent (press in the skin surface to the back layer of the eyelid)---- This seems straight forward enough; but perhaps without much anatomic knowledge of the layers within the eyelid, and the goal was to be quick and without any need to cut skin. It worked for patient with thin eyelid (without any skin & fat excess; which then will exclude a lot of single-eyelid people)--- and is still used today by people who want a quick fix. I believe that in some Asian countries, one can get it done quickly in beauty parlors or by general doctors. People are seemingly accepting of the fact that the crease created this way may last only several years.



This illustrates the typical buried sutures methods which uses three sets of buried sutures that loops around the layers within the upper lid muscles.



Above drawing shows passages of buried sutures; what is left behind within the lid are the fragments represented by dotted lines from A to A', B', then B, and then A is tied to B to form a knot and buried under the skin. A' and B' actually passes through the back layer (7<sup>th</sup> layer, conjunctiva) of the lid higher than the tarsus to create a crease along the line we show here; while A and B comes to the front side through skin (the first layer).

The method is a bit faster, it's a bit cheaper; and the doctor may not have followed that patient long enough to see the long term results as both the patients and doctors seem to consider the procedure as benign.

Subsequently there have been many variations of this "no-cut methods" (they should have called it "buried sutures technique using permanent non-dissolvable sutures")--- even now I come across patients seeking revision who are not aware that there were permanent sutures remaining within their eyelid. Often the crease created appears "static", and showed dimpling and irregularity on the compressed crease line especially when the lid is looking down or shut. If you imagine your tailor had put 3 stitches through the full thickness (or 90-95% of the component layers of your upper lid) and tied a tight knot for each of these three, you get the idea of how compression through soft tissues can create a choked indentation. Sounds tight to me!

With current knowledge my own professional view is that the upper lid is far too complex in dynamics and function to tolerate implantation of permanent loops of sutures through 6-7 layers of tissues (each does different functions) without a full understanding the long term effects, whether hindering or losing its effectiveness.

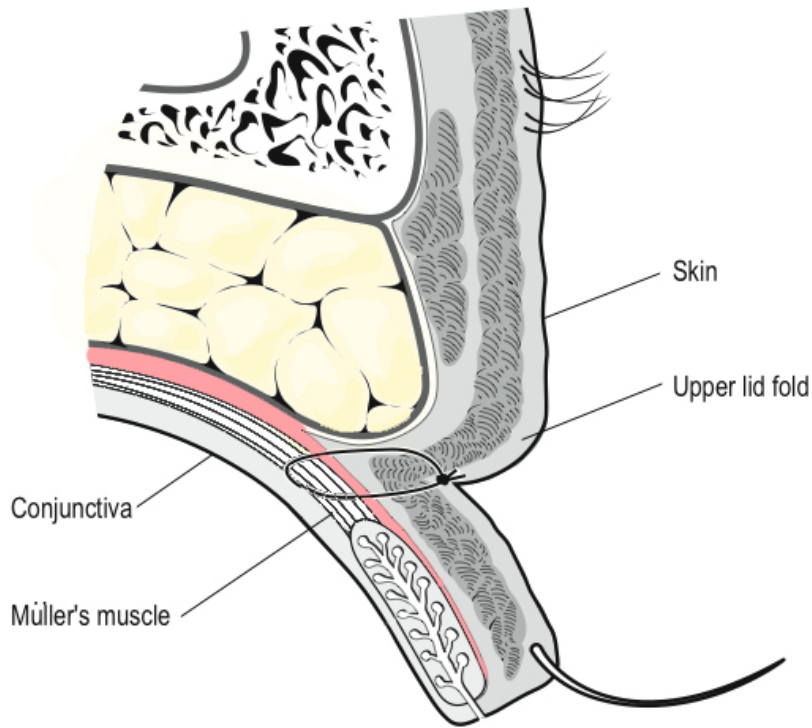
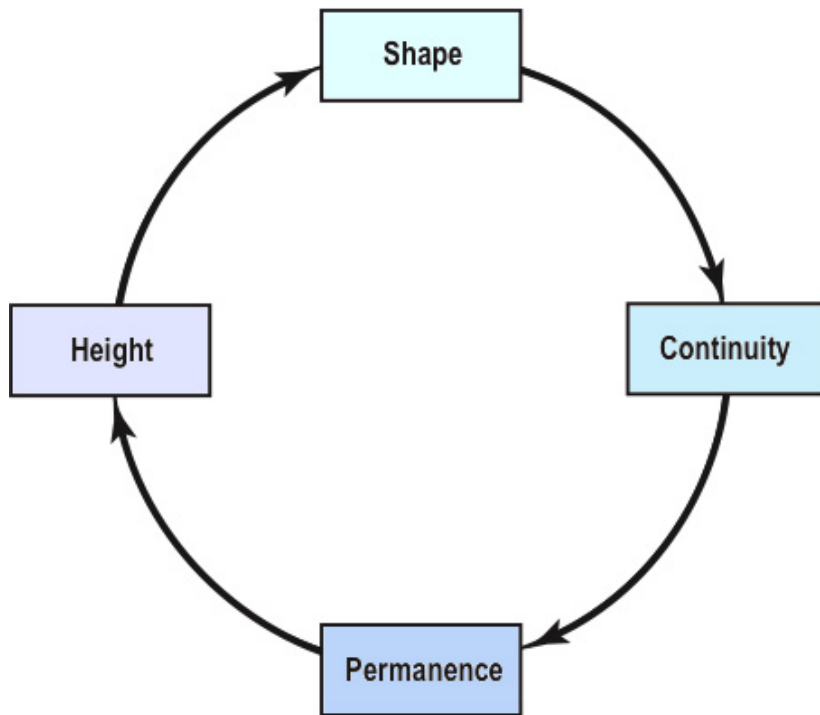


Diagram above shows use of permanent buried sutures across the thickness of the upper lid to form a constriction-induced crease ( by buried sutures methods).

Though some number of young patients still choose this option in Asia and even here in North America, more people have come to realize that when it comes to control of factors such as crease HEIGHT, its SHAPE, whether it appears natural and continuous (CONTINUITY), and the rate of disappearance of the crease over time in some cases (PERMANENCE)---these are benchmark ( goals) I have always stated as essential, and published in my Asian Blepharoplasty surgery textbook since 1995.



We should aim for a dynamic crease, shouldn't we?  
Tell me, *who does not want to have a dynamic crease?*

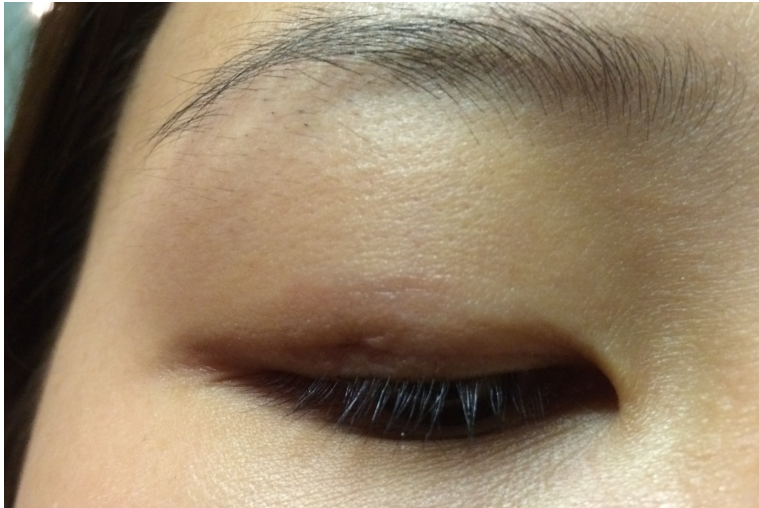One should not depend on the use of buried permanent stitches, that's too crude in my mind. What if you have some excess skin fold or fat that just wouldn't go away with use of buried suture methods? These individuals are not be a good candidate according to the published papers.

I had the pleasure of talking to one of the pioneer in Asian eyelid surgery, Dr.Boochai of Singapore about ten years ago when I was finalizing the Second Edition of my book(2005), quizzing him on what percentage of his patients within his own practice he would recommend the buried sutures method, his answer was that in less than 5-10% can be candidates for use of the simplified buried sutures method.

Some of the consequence in some patients who had underwent the buried sutures procedures ('no-cut', 'mini-incisions') may include a sensation that something is bothering them within the eyelid layers (foreign body sensation of the eye), an initially raised(tightened ) upper lid opening, followed some 1-5 years later by a drop in their elevator muscle, sometimes the crease disappear or fade away partly because the tight knots loosens in some cases, or cheese-wire through soft layers. They may have some reduction in how far their upper lid can reach downward when looking down, and of course the static appearance that there is still an indentation when the person looks down ( this static, unchanging nature of the



crease appearance is a hallmark of someone who has had surgery by buried sutures method; though it can occur also in incision methods if the doctor had not designed a good crease).

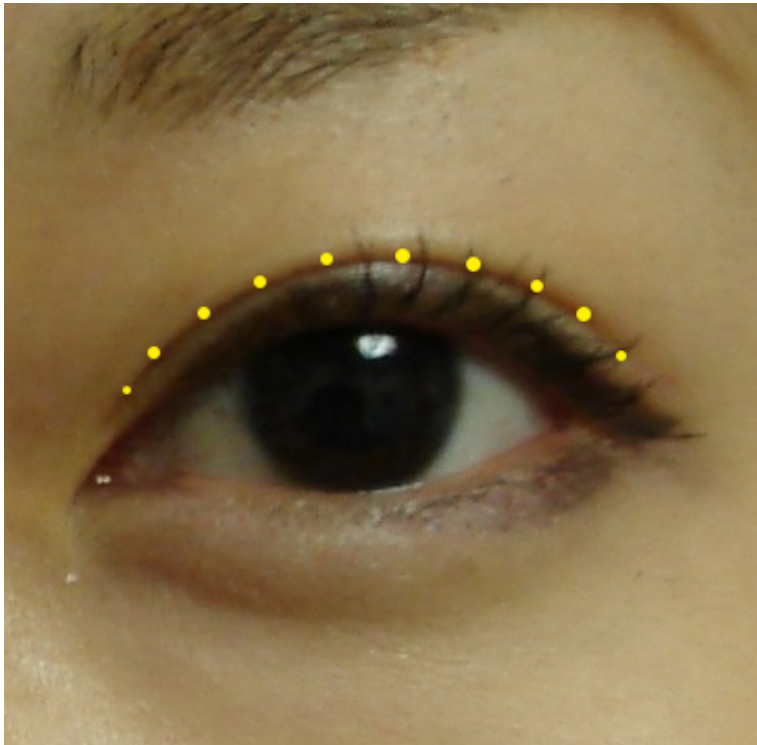


Above: Buried suture method created an indented crease that was set low, and then disappeared. What is left are small skin dimple from buried sutures, you can see one in the mid-section.

To convert a single eyelid without crease to a double-eyelid (with a crease) sounds simple, but the quest for a dynamic crease will depend on thorough understanding that there are unique variations even among Asians who are single-lided, an understanding of eye functions, the biological dynamics of the layers, geometry, viewing angles, ratios of real crease and dimensions versus what is observed, physical factors of the person's face (size of eye opening, shape of fissure, corner to corner distance and all kinds of stuff one probably are not yet aware of.)

Face it, to have a good dynamic, permanent, and natural crease takes time and effort—after all a lot of people have tried make-ups, glues, tapes, strings or combo of these besides manipulations and eyelid exercises, over much time wasted. If you decide to go for surgery, shouldn't it be something thorough and blends with your anatomy, does not involve implanting suture loops that are like nooses, and takes care of excess tissues while creating good relationship among the seven layers?

Well, to create this dynamic crease, envision that a string of these nano-sized pivot *points* will need to be created to reflect what we see in a naturally born crease. Do it gently and effectively, no gimmicky buried sutures that can cause problems later. The technique may require ( I should say, definitely it *does* require) higher learning and greater degree of clinical skill set and dexterity.



Did you notice the nano-bobas are of varying sizes?

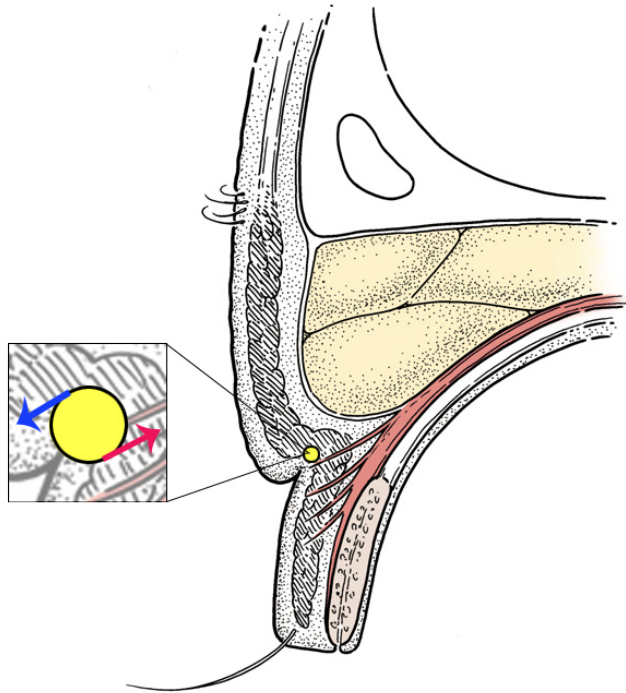
If you think of the upper lid like China's Great wall, each section has different slope and curves and forts and garrisons. From a satellite's view down, it may look homogeneous and uniform but it is not. So the lid's mid-section is different from the inner one-third and the outer one-third.

As the surgeon goes along the curved surface and the eyelid layers comes in and out, how can one maximize the efficiency of pivot between front and back layers *at each point* so that when combined they work like a synchronized and choreographed natural crease?

That's what we do, a "Nano-boba concepted Asian Blepharoplasty by CHEN" (in my publication I have termed "A stringed serie of Uni-points"—but then, only a Math major or engineer would like this term). I have actually talked about this concept in some form since my 1996 paper in the Plastic and Reconstructive Surgery Journal.

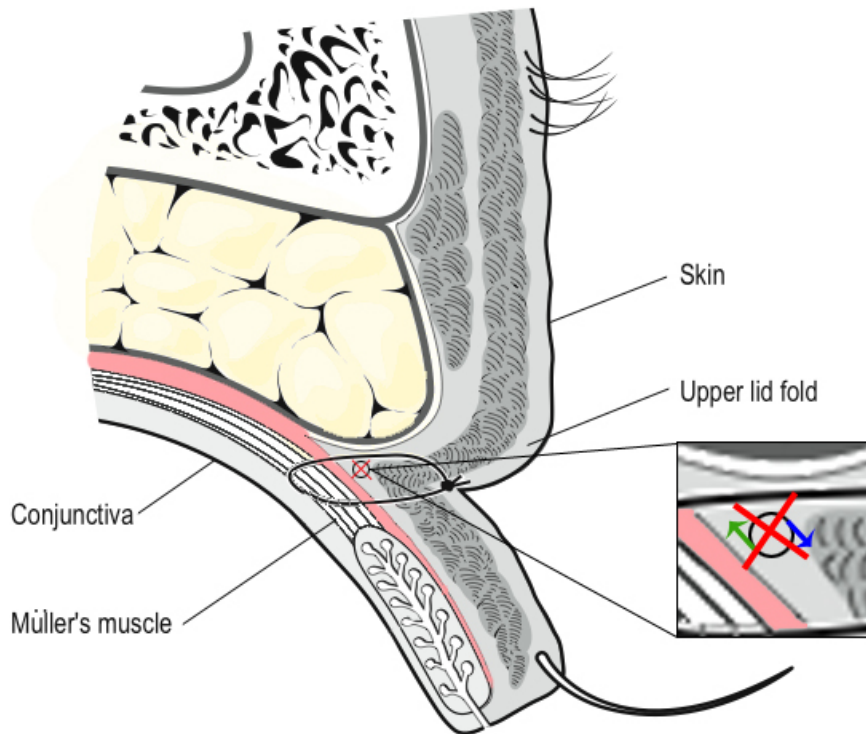
My technique at every step (there may be ten steps I last counted) combine to make this possible, no sutures are left in since all skin sutures are removed at one week after, and achieve the benchmarks I set for the four important goals.

Does every person get unanimous success? No, not every single one; but only 5% needs touch-up among the thousands of eyelids we have worked on( by Dr.WPD Chen). That's pretty good stats being that no two individuals have similar anatomy.



*Normal state*

Natural Crease: Here again is the drawing show the critical junction where the back layer is pulled up (red force) and the front layer(blue gravity force) comes down to form a minimal fold over a naturally-born crease. It is as if there's a series of freely rotating (pivoting) nano-bobas for people with a natural eyelid crease.

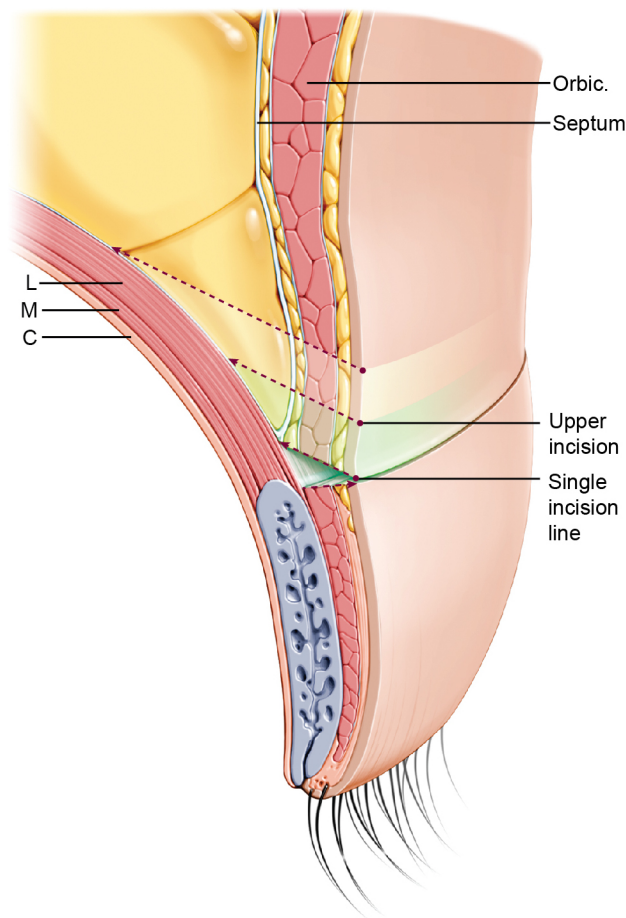


After buried suture techniques including DST etc.

Single-eyelid without crease, having received buried sutures methods: The use of permanently buried suture loops just happens to destroy any chance for a good nano-boba function because it chokes the muscle's function to create a non-physiologic depression and mimics a crease. I consider these a false crease. It tends to lock up the levator (in pink) to the skeletal muscle (in darker gray) just below the skin since it is placed several millimeters above the upper edge of tarsus. The one to three loops of buried sutures used here can affect the proper functioning (contraction of the levator muscle) in a negative way even in those people born with a crease.

Even if some buried sutures are intentionally chosen as dissolvable, they can create permanent bonding of these free tissue layers within each eyelid.

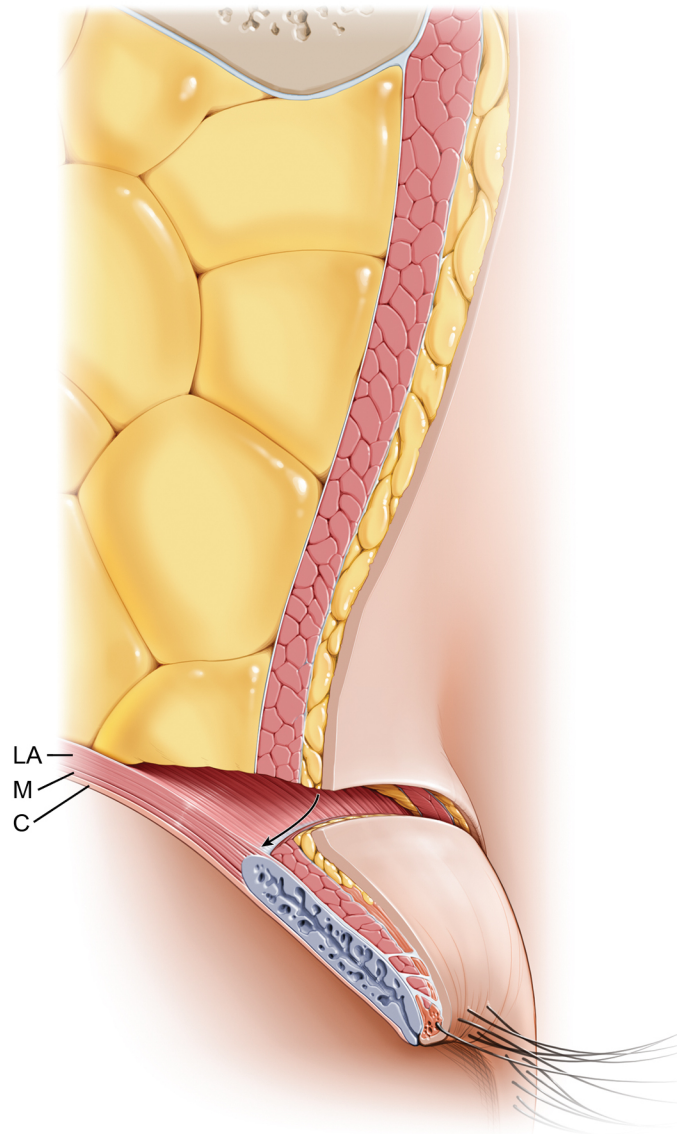
In our technique (AB by Chen), the crease line is marked exactly (as compulsively accurate as humanly possible), with selective removal of small amount of tissue layers like skin and fat, as well as proper positioning of the layers after this, and fine stitching at the exact points for nano-bobas along the desired crease form; these efforts will get us a dynamic interaction.



Asian Blepharoplasty by Chen. (AB by C)

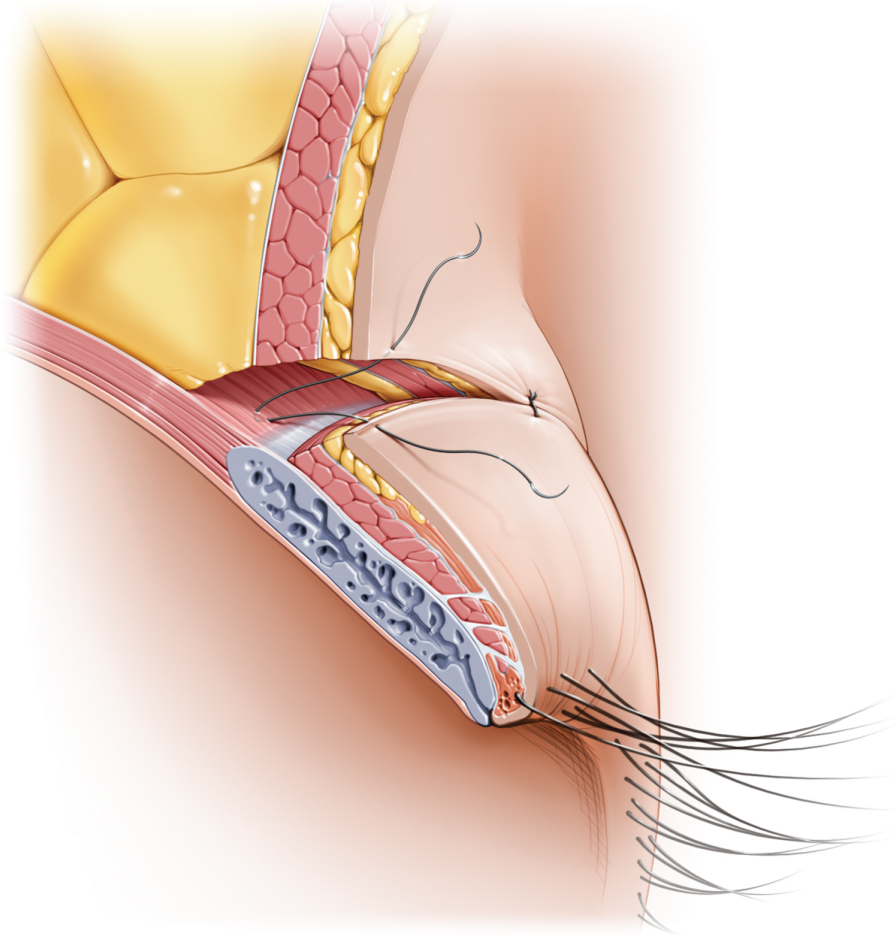
So you see that the nano-boba functioning is actually mimicked through proper creation of the relationships that did not exist before, with steps we use in AB by Chen.

This is possible for as long as LA (= Levator muscle) is healthy and in the right position. If that is weak, this condition of ptosis has to be corrected first.



(Above): *AB by C* after small amount of tissues are strategically removed, correcting the deficiency and allowing the dynamic forces to act properly. Arrow shows the upper skin edge lie on to the lower edge nicely without tension.

Below: The edges of the skin are then partly united with some surface strands of the levator to allow this levator muscle to drive the crease which is what we should see in normal physiology; no buried suture is used.



I use these temporary external sutures which are all removed by me at one week. Upon completion, a successful crease is actuated by the levator strands and it follows the physiologic function as if it has the nano-bobas in place.

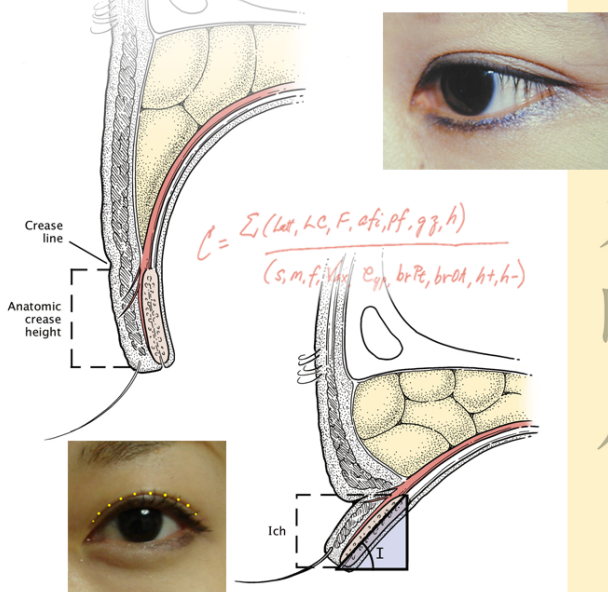


Dr. William Pai-Dei Chen  
 Private Practices in Irvine, Newport Beach, California  
 Clinical Professor of Ophthalmology  
[www.asianeyelid.com](http://www.asianeyelid.com)

(This is a simplified discussion to help disperse information about techniques used in my eyelid surgery practice. It is not meant to serve as a guide in your choice of procedures or providers. You should do your own medical research. Interested readers for more detailed discussion on a professional level can consult any of my textbooks present and future, or search for references through online resources of the National Library of Medicine.)

## The Eyelid Crease and Double Eyelid Surgery

(what you need to know)



双眼皮

陈伯迪

William P. Chen, MD  
 Katherine L. Chen